

## **From Our Office to Yours...**

*The goal of periodontal therapy is to establish and maintain the dentition (which today includes both natural and implanted teeth) and the periodontium in health, comfort and function with optimal esthetics throughout the lifetime of our patients.*

*Esthetics is not a new objective. It always has been an integral portion of the overall treatment goal. What is new is that we currently have a variety of periodontal plastic techniques to enhance esthetics through the sophisticated management of soft tissues and bone.*

*This current issue of **The PerioDontaLetter** reviews the objectives of periodontal plastic surgery along with the indications and techniques for treatment.*

*We are excited about working with you to meet your patients' reconstructive and esthetic needs and desires.*

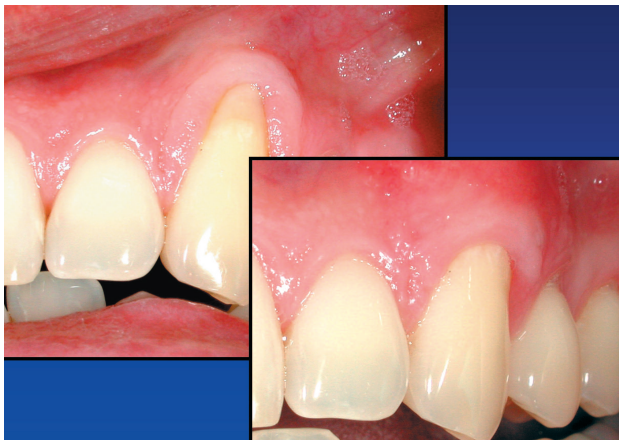## **Periodontal Plastic Surgery to Produce an Esthetic Result**

**T**he term periodontal plastic surgery, previously referred to as mucogingival surgery, broadens the scope of periodontal surgical treatment.

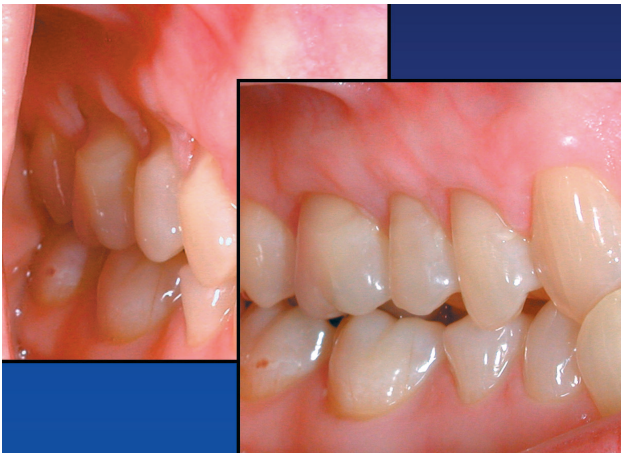
This new term more accurately reflects the current evolution in techniques which enhance the function and esthetics of the periodontal tissues and permit management of many defects previously thought to be untreatable.

The objectives of periodontal plastic and reconstructive surgery have expanded beyond treatment of recession and problems associated with attached gingiva to include: gingival augmentation, elimination of the aberrant frenum, coverage of exposed roots, preservation and regeneration of the alveolar ridge after tooth removal, and esthetic crown lengthening.

The long-term success of treatment will be determined by



**Figure 1.**  
*Recession and subsequent root exposure on the maxillary canine was repaired with a connective tissue graft.*



**Figure 2.**  
*Teamwork between the periodontist and the restorative dentist using connective tissue grafts and Class V restorations repaired this patient's recession and tooth loss.*

The indications for gingival augmentation are: soft tissue recession and root exposure, and minimal or no attached gingiva. The presence of thin gingiva is also an indication for gingival augmentation.

### **Elimination of the Aberrant Frenum**

The mandibular frenum is evaluated by its proximity to the gingival margin and the morphology of the gingival complex.

A frenectomy is commonly performed in conjunction with a soft tissue graft to increase the amount of attached gingiva and eliminate the aberrant frenum at the same time.

The maxillary frenum is usually evaluated by additional criteria. Because a shallow vestibule is rarely a problem in this area of the mouth, apical positioning of the frenum or total

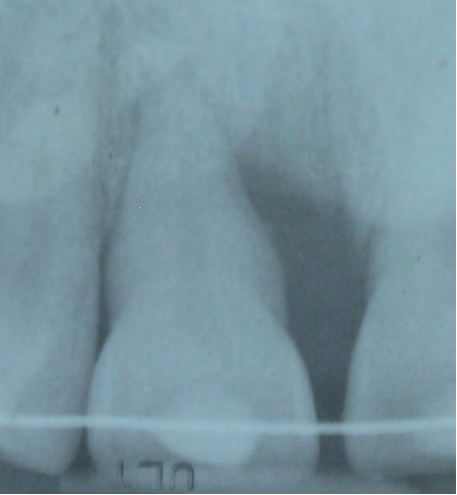how well the etiologic factors are identified and eliminated. For example, the etiology of gingival recession must be addressed or the success of root coverage procedures will be compromised.

It is important that the clinician combine current knowledge of the literature with personal clinical experience to determine the best treatment plan for each individual patient based on the diagnosis of the specific problem. The elimination of gingival inflammation should always be the first step in periodontal therapy.

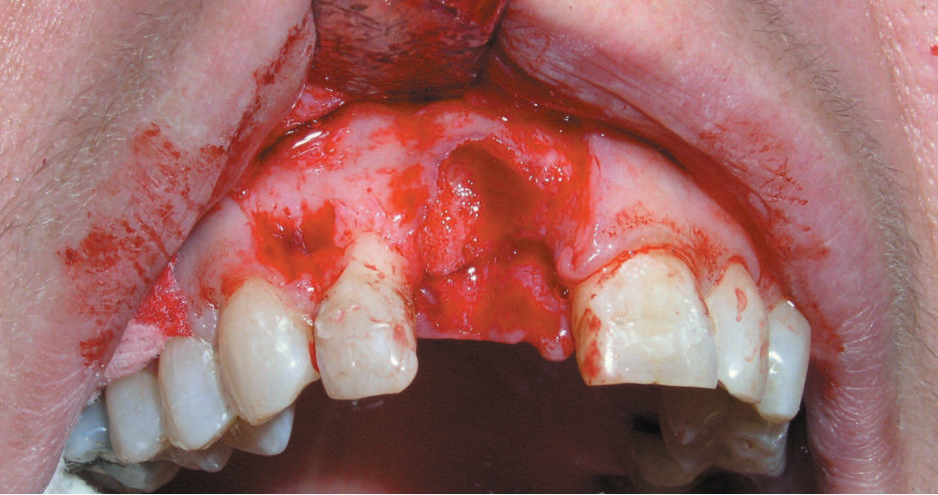
The indications for periodontal plastic surgery assume that control of inflammation has been successfully implemented.

### **Gingival Augmentation**

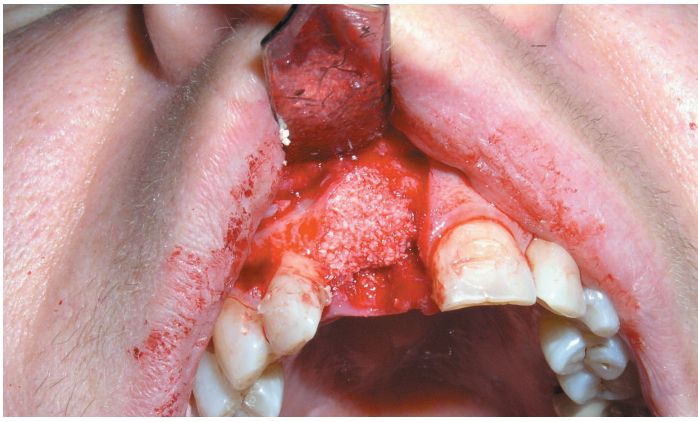
The objectives of gingival augmentation and regeneration are to increase the width and thickness of gingiva, establish a proper vestibular depth, prevent or stop soft tissue recession and facilitate plaque control.



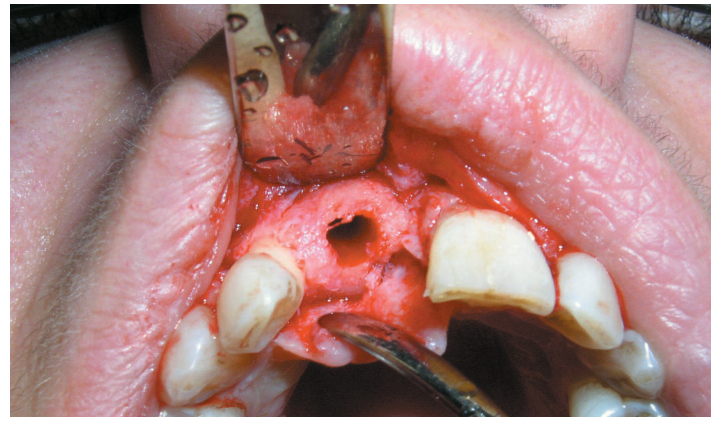
**Figure 3.**  
*The upper right central incisor had a hopeless prognosis and needed extraction.*



**Figure 4.**  
*The loss of the buccal plate was revealed on extraction. (See Figures 5 and 6 on page 3.)*



*Figure 5. A socket preservation graft was performed to facilitate implant placement at a later date.*



*Figure 6. The socket preservation graft healed to create sufficient bone to permit preparation of an implant osteotomy.*

elimination of the frenum are the most common goals.

## Coverage of Exposed Roots

Gingival recession with root exposure is often associated with lack of attached gingiva, trauma, inflammatory periodontal disease and occlusal forces.

The objectives of root coverage procedures are to improve esthetics and/or cover cervical root defects, root caries, or root sensitivity.

**The amount of root coverage one can expect to achieve is limited to the height of the adjacent interdental bone.**

Cervical root defects can be caused by cervical abrasion, erosion or abfraction. The increase in incidence and severity of cervical tooth defects has become the most overlooked indication for root coverage surgery. When the exposed cervical root defect is left untreated, it can progressively deepen and lead to tooth loss.

The coverage of exposed roots by periodontal plastic surgery tech-

niques may assist in halting the progressive nature of these defects.

Today, subepithelial connective tissue grafting currently is the most commonly used procedure for root coverage.

Other common root coverage procedures include a variety of pedicle grafts and guided tissue regeneration using resorbable and nonresorbable barrier membranes.

In a comparison of periodontal plastic surgery procedures Rocuzzo et al found that connective tissue grafting was more effective than guided tissue regeneration in obtaining root coverage.

Ideally, both root coverage and restorative techniques are needed to reestablish a proper tooth length and to repair the cervical defect.

## Alveolar Socket/Ridge Preservation and Augmentation

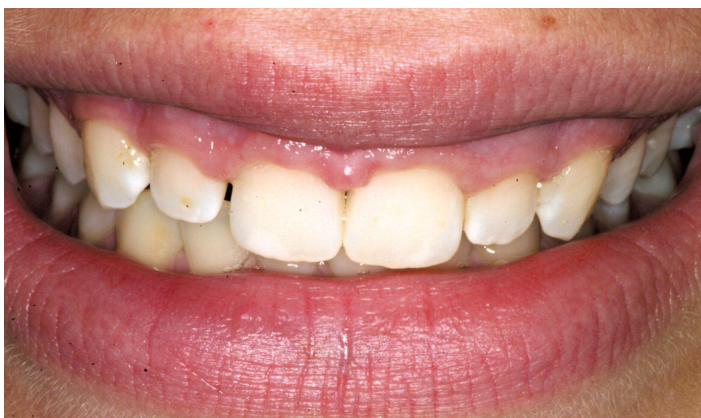Alveolar ridge defects occur most commonly when the loss of teeth results in a dimensional loss of bone and soft tissue surrounding the

alveolus. The problem of ridge defects has been primarily esthetic. However, ridge defects may create functional problems as well.

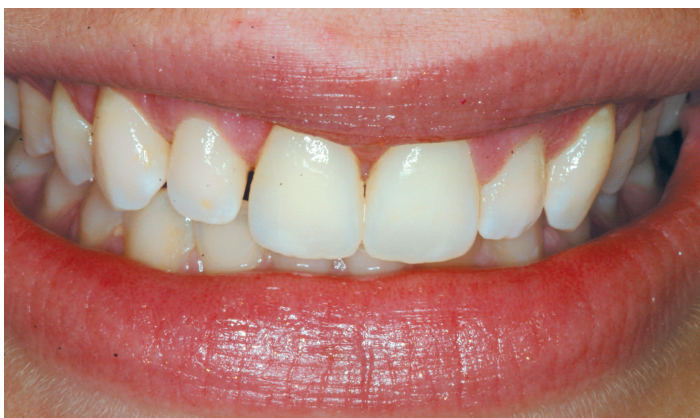The current thinking is to prevent ridge defects at the time of extraction rather than reconstructing a resorbed ridge. There is a substantial body of literature which indicates that rapid and severe resorption will occur immediately following tooth extraction if no steps are taken to minimize or avoid it.

Ridge preservation may be achieved by extraction socket preservation. Grafting of an immediate extraction socket will often prevent collapse of the ridge which can result in an esthetic or functional defect. Subepithelial connective tissue grafts are also commonly used for ridge augmentation and may be used in conjunction with bone grafting.

If any tooth is going to be removed, and especially if implants are anticipated, the clinician must plan to provide hard and soft tissue regeneration at the time of tooth removal to prevent an esthetic or functional defect. It



*Figure 7. This young woman presented with short clinical crowns as a result of altered passive eruption.*



*Figure 8. Two weeks following esthetic crown lengthening, the cosmetic benefits are readily apparent.*

is much easier to prevent a cosmetic or functional defect than to repair it.

## **Esthetic Crown Lengthening**

Esthetic crown lengthening may be indicated when anterior teeth are shorter than normal or when excessive gingival display is the problem. A gummy smile can be the result of gingival enlargement, altered or delayed passive eruption, short clinical crowns, vertical maxillary excess, a short upper lip or orthodontic deformities.

Crown lengthening can be achieved with apically-positioned flaps to expose more tooth structure and can be performed with or without osseous surgery.

In many cases, it is not sufficient to simply remove gingiva. If the crestal bone is located close to the cemento-enamel junction, it is incumbent upon the clinician to remove sufficient bone to

reestablish a proper biologic width. Otherwise the resected gingiva may grow back or if restorations are anticipated, there will be a violation of the biologic width resulting in gingival inflammation.

Proper crown lengthening allows new veneers or crowns to have the correct length, width and shape for an esthetically pleasing smile.

Esthetic crown lengthening involves sculpting the patient's gum line to achieve proper esthetics. When restorations are anticipated, crown lengthening will permit restorations of proper length and shape producing an esthetically pleasing smile.

When managing altered passive eruption (where the tooth did not erupt sufficiently from the alveolus), the principles of crown lengthening apply regarding the management of soft and hard tissues. In addition, one must consider the amount of attached gingiva to avoid compromising it.

Achieving the ideal position of the gingival margin requires 3mm between the CEJ and the osseous crest. This will permit restoration with an ideal biologic width as well as ideal position of the gingival tissue. Removal of crestal bone will not compromise the tooth's stability.

In our culture, the ideal smile exposes a minimal amount of gingiva. Gingival contours should be symmetrical and in harmony with the upper lip; anterior and posterior segments should be proportionate to each other, and the teeth should be of normal length and width.

Achieving esthetic results is a partnership between the general practitioner and the periodontist.

Planning cases together will enable us both to provide your patients with the most attractive smiles possible.

