

From Our Office to Yours...

The maxillary posterior teeth are most often the first to be lost in chronic periodontal disease. Not only does periodontal disease reduce the maxillary bone height but, as we age, the maxillary sinus expands into the alveolar ridge. This reduces the alveolar ridge height beyond that which may occur during the repair of an extraction socket and the subsequent alveolar ridge resorption. This is often exacerbated by long term use of removable prosthetic appliances.

These factors make the maxillary posterior the most difficult area in which to maintain or increase the alveolar bone support needed for implant care. Additionally, the bone quality tends to be softer (Type 3 & 4) in an area which must be capable of absorbing the heaviest occlusal forces.

This current issue of **The PerioDontaLetter** discusses when and how the quantity and quality of bone mass can be increased in the maxillary posterior segments. As always, we will be happy to consult or assist you in the diagnosis and treatment of potential implant patients with alveolar ridge deficiencies.

The Management of Inadequate Bone for Maxillary Posterior Implant Cases

Dental implants are the most successful of all implanted medical devices. They are more successful than knees, hips and other prostheses. However, there are still areas of the mouth where predictable dental implant therapy remains difficult, if not impossible. The most prevalent of these areas has been the posterior maxilla.

There are two major problems faced by clinicians preparing for maxillary implants.

The first problem is loss of alveolar ridge height in the maxilla due to decrease in coronal height from periodontal disease and decrease of apical height due to expansion of the sinus into the alveolar process.

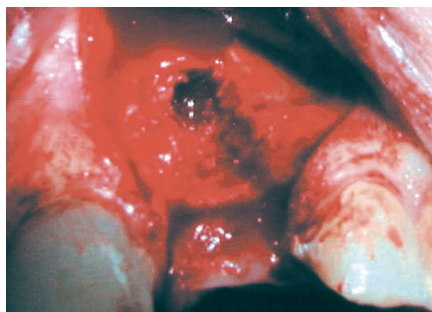


Figure 1. At the time of extraction, the obvious loss of buccal plate due to a root fracture is revealed.

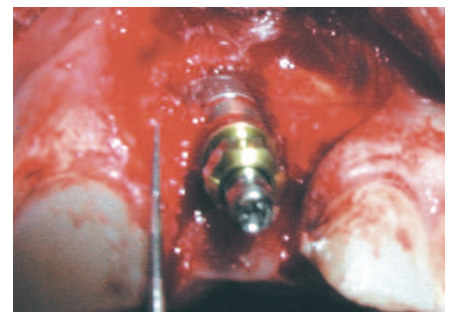


Figure 2. Implant placement at the time of extraction required correction of the buccal dehiscence.

The second major problem is loss of buccal-lingual width in the maxilla.

Several procedures are available to increase the available quantity and quality of bone in the maxillary posterior segment. Procedures used to increase residual ridge width include lateral ridge augmentation and ridge splitting. Areas of inadequate ridge height can be corrected by either uplifting the sinus floor or by vertically grafting the alveolar ridge to add height.

The main question is how to determine which method of increasing the alveolus is the most appropriate to insure the successful integration of the dental implants and the fabrication of a comfortable, functional, and esthetically pleasing implant restoration.

Vertical Ridge Grafting

The most difficult of these procedures is vertically grafting the ridge in an occlusal direction. Vertical augmentation is desirable when the space between the upper ridge and the lower teeth has increased at

the expense of the crestal alveolar height. The excessive inter-arch distance results in very long, unattractive teeth and pontics, an unfavorable crown to implant length ratio, and unnatural looking prostheses.

This problem cannot be resolved by sinus grafting alone. Although sinus grafting may raise the sinus floor sufficiently to place implants, it does not resolve the tooth length problem. Increasing alveolar height is, therefore, necessary, in addition to vertical augmentation, and this is the least predictable method to increase available bone for dental implants.

The use of titanium reinforced membranes to create space, osteoinductive and conductive grafting materials, and autogenous, onlay block grafting have been attempted with variable success rates.

Patients undergoing this type of procedure are prohibited from wearing any form of removable prosthesis for at least six weeks, because any pressure upon, or micro-movement of, the graft material, will cause failure of the graft.

When there is adequate height of the residual maxilla between the sinus and the crest of the residual ridge, but inadequate buccal-lingual width for implant placement, vertical ridge augmentation, ridge splitting, lateral ridge augmentation, or a combination of these procedures may be employed to expand the buccal-lingual width of the posterior maxilla.

Lateral Ridge Augmentation and Ridge Splitting

Lateral ridge augmentation is the most commonly selected procedure for correcting isolated ridge concavities. Ridge width deficiencies (3mm or less) force the implant to be positioned in an excessively lingual and poorly-angulated position. This results in restorations which are unattractive and have an improper occlusal relationship with the opposing dentition.

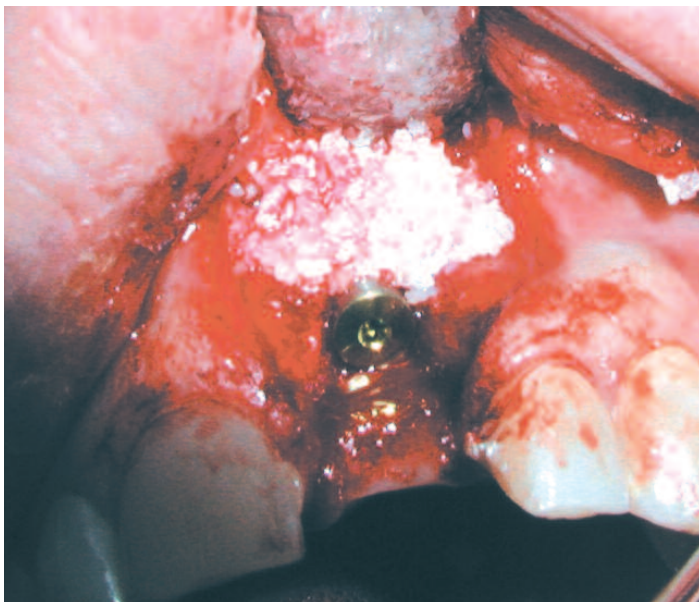


Figure 3. A bone graft was placed and covered by a guided tissue membrane to create the needed buccal bone support.

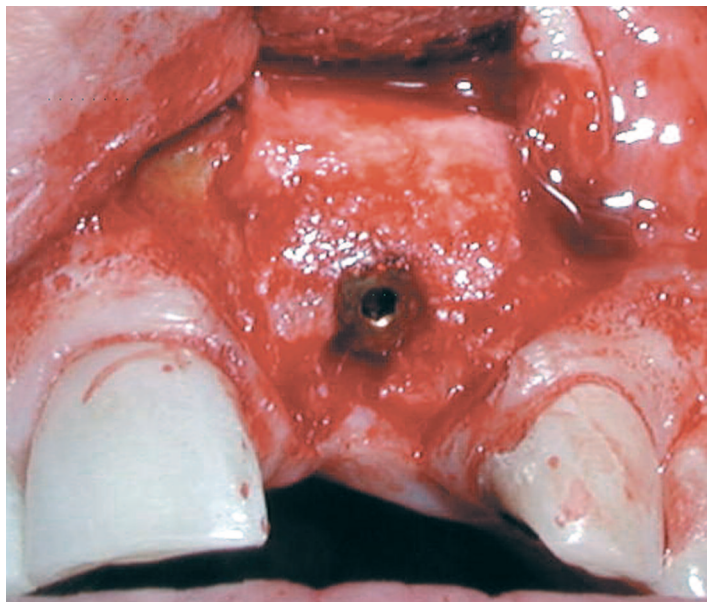


Figure 4. At the implant uncovering, the success of the procedure and the newly regenerated bone can be observed.

When the ridge width is only slightly narrow, with observable cancellous bone interspersed between the cortical plates, the ridge splitting technique may be utilized. Osseous grafts fill the ridge split channel which is created by utilizing burs, osteotomes and/or specially designed tapered chisels. It is important to utilize a split thickness flap, which maintains a connective tissue/periosteum covering over the bone and provides continuity of blood supply to the widened ridge.

Depending on the diagnosis, treatment plan and overall width of the separated bony plates, the implants may be placed at the time of the ridge split or between four and six months later.

Sinus Floor Augmentation

If the clinical presentation includes pneumatization of the sinus, a residual ridge of sufficient width and an inter-arch distance which is within the normal range,

localized sinus floor augmentation grafting via osteotomes may be the procedure of choice to increase the quantity of available bone for implants.

Successful implementation of this technique is dependent upon 4 - 8 mm of bone between the sinus floor and the crest of the residual maxillary ridge. One may reasonably expect to achieve 3-

5mm. of sinus floor elevation utilizing this technique.

With sufficient quantity and quality of crestal alveolar housing, implants can be placed at the time of sinus augmentation, or delayed for 4 -6 months to permit consolidation of the graft. Advantages of this approach are the non-invasive nature of the surgery and the predictability of the results.

Figure 5. The diagnostic radiographic stent locates the ideal implant position and the x-ray reveals inadequate bone height and a divided maxillary sinus.

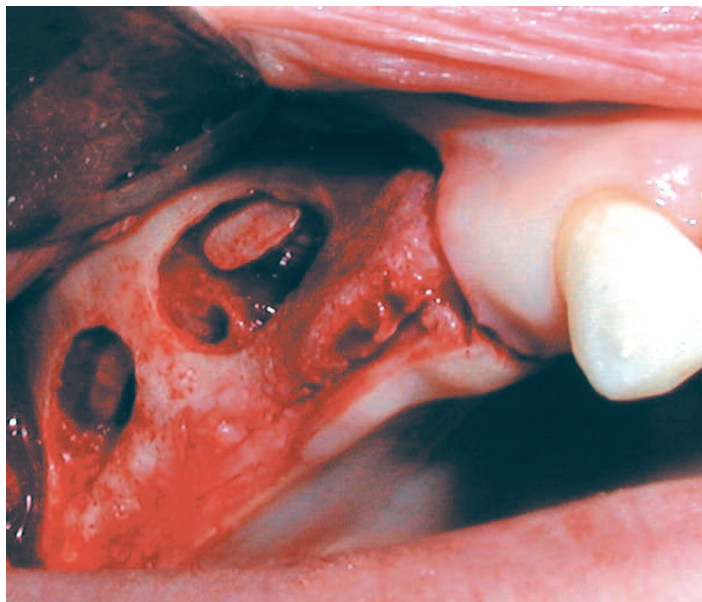
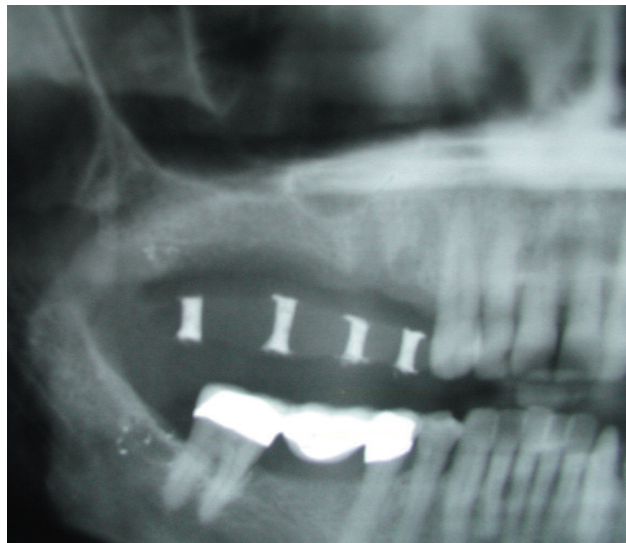


Figure 6. A lateral wall sinus lift (Caldwell Luc with sinus membrane intact) was performed on both sides of the vertical septum dividing the sinus cavity.

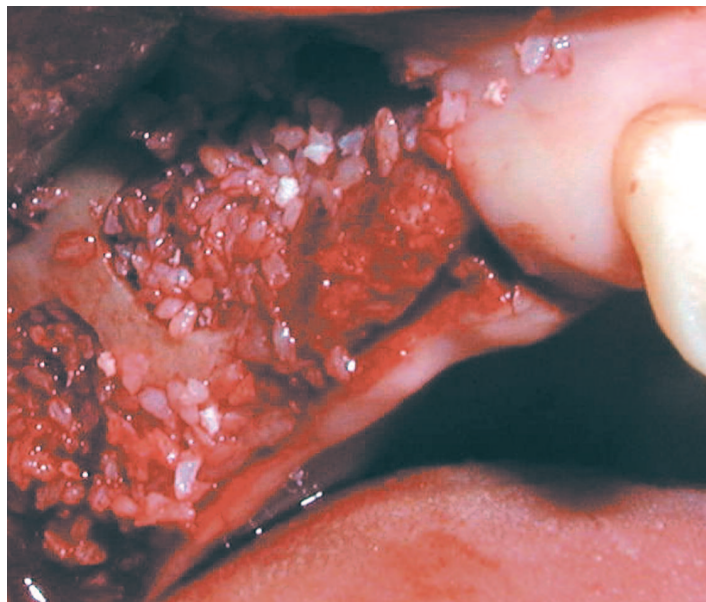


Figure 7. Sinus bone grafts were placed to stimulate osteogenesis and create sufficient vertical bone height for subsequent implant placement.

The methodology of this procedure produces an "up-fracturing" of the sinus floor while maintaining the integrity of the Schneiderian membrane. An osteotomy is prepared to within 1 - 2 mm. of the sinus floor, utilizing burrs or osteotomes. The osteotomy site is "back-filled" approximately 2 mm. with a suitable bone grafting material. An osteotome is employed and the graft material is gently tapped in a superior direction against the sinus floor. This approach, when done carefully by experienced clinicians, produces an "up-fracture" of the sinus floor and membrane. The result is a localized "tenting effect" in an apical direction. The graft material, sinus floor, cortical plate and intact membrane support the "tent" and produce, over time, the identical effect as guided bone regeneration in other applications.

Sinus Elevation

When the distance from the floor of the sinus to the residual crest of the ridge is less than 4mm, and multiple implants are anticipated, requiring a more substantial graft, a lateral window, open (Caldwell Luc) sinus elevation technique may be indicated. This procedure has the advantage of affording the clinician direct access and visualization of the sinus cavity and control over the size of the grafted site. The disadvantage is that the procedure is significantly more invasive than a bone-added, osteotome, sinus floor elevation.

The open technique relies upon locating and mapping the sinus and its contents radiographically. An entry window is prepared, typically between the maxillary first bicuspid and first molar. This window is typically oval and is prepared by outlining it with a high speed diamond, until the sinus membrane is visible. As the membrane becomes exposed, the clinician can observe a blue-grey change in color.

Blunt ended instruments are used to carefully separate the delicate sinus lining from the adjoining bone. The remaining eggshell of buccal bone is fractured inward and upward (similar to a trap door) and becomes the new superior floor of the sinus.

The sinus membrane is further dissected anteriorly, medially and distally to create a four-walled cavity which is completely lined by the intact Schneiderian membrane and former buccal plate of bone.

Bone Grafting Materials for the Sinus Cavity

The prepared sinus cavity is now filled with appropriate bone grafting materials. These may include autogenous, allograft, xenograft or synthetic grafting materials.

Many clinicians support the use of a combination of more than one type of grafting material. All, however, agree that the more autogenous bone in the mix the better.

It is desirable for the grafting materials to have osteoinductive and osteoconductive potential. The assumption is that autograft material delivers the greatest amount of BMP (Bone Morphogenic Protein), which has the potential to "jump start" the process of bone regeneration. Human growth factors, such as Platelet Rich Plasma (PRP), are purported to hasten the regenerative process and decrease the healing time.

Recent research advances in "tissue engineering" promise the future availability of BMP and other laboratory produced growth factors.

If there is available crestal bone of satisfactory quality and quantity to provide initial support, implants may be placed at the same time as the sinus grafting procedure. If there isn't sufficient bone to stabilize and prevent micro-movement of the implants, delayed (6-12 months) placement is recommended.

Advances in oral radiology have increased the accuracy of pre-implant surgical diagnosis and enhanced the overall treatment planning process. The result has been to minimize the incidence of intraoperative "surprises," thereby increasing the success rate and predictability of sinus grafting.

Using 3D Reformatted CT Scans of the maxilla, it is now possible to determine the exact size of the residual ridge and the precise volume of grafting material required, prior to the surgery. Furthermore, when sinus grafting is indicated, CT Scans can be used to confirm the health of the sinus, thus reducing the risk of post-operative infections and other complications. This is especially important in patients with a history of sinus infections, allergies or sinusitis.

As a result of these advances in dental implant technology, there are now so many more patients who can be restored with dental implants. Since we can now predictably determine where we can rebuild missing bone structure, restoring these individuals with dental implants is simply a matter of determining which direction we need to grow bone and how many implants we need to restore them to proper function.

We hope this review of the site preparation process for maxillary posterior implants helps you in evaluating, making decisions and explaining implant procedures to your patients. Implants are no longer a last choice for the dental cripple; they provide absolutely the best method of tooth replacement, from a biologic, functional and cosmetic standpoint.

Truly they represent the current "Standard of Care."

